

FRACTIONAL/PIXEL CO₂ LASER AS A TREATMENT OPTION FOR LICHEN SCLEROSUS

¹Jorge A. Elias, MD and ²Miriam Galich, MSc

¹ Gynesthetic Salud y Estética. Aesthetics Gynecology Clinic, Buenos Aires, Argentina

² University Buenos Aires, Argentina

Abstract

Contemporary lichen sclerosis (LS) treatment modalities suffer from dependence on long-term patient compliance and high recurrence rates. The Fractional/Pixel CO₂ laser has been applied to treat skin disorders and induce vaginal rejuvenation and may overcome the drawbacks of current treatment options.

Two postmenopausal LS patients resistant to conventional therapies, were treated with Fractional/Pixel CO₂ laser. The patients became asymptomatic shortly after the third

treatment, and the vulva, introitus and clitoral areas looked healthy throughout the 6-month post-treatment follow-up period. Histological assessments showed a trophic epithelium with acantotic areas, without superficial hyperkeratosis or the hyaline and eosinophilic collagen bands characteristic of LS.

Conclusion: If confirmed in a large group of patients, this treatment concept might represent a new strategy for providing more than just symptomatic relief for a myriad of soft tissue conditions.

Jorge A. Elias. Vuelta de Obligado 2357 8°A - Ciudad de Buenos Aires - República Argentina - Tel +541147880219, drjorgeelias@gmail.com

Introduction

Lichen sclerosis (LS) is a chronic, inflammatory skin condition, most commonly occurring in adult women, although it can also be seen in men and children. It primarily affects the genital and perianal regions, where it causes persistent itching and soreness. Scarring after inflammation can lead to severe damage, including fusion of the labia and narrowing of the vaginal opening, if treatment is not initiated at an early stage.

Biopsy to rule out squamous cell carcinoma is recommended in all patients suspected of having LS. Spontaneous remission is extremely rare, and affected people have an increased risk of genital cancer. [1,2]

Therapeutic agents for LS include topical corticosteroids, which require continuous administration and patient adherence. A review of six

treatment protocols is available in the Cochrane library [1]. Surgical approaches include vulvectomy and cryosurgery, however, these procedures leave scars on the damaged tissues and are associated with high recurrence rates. [3]

Superficial ablation of LS by means of a CO₂ laser has been known for a long time. [3-4] While considered a standard in-patient procedure, the technique requires use of general anesthesia and a healing period of 6 weeks.

The high cost of laser tools and the need to perform such procedures in surgical facilities, have seemingly limited widespread embracement of CO₂ laser ablation strategies by physicians and patients. However, advancements in fractionated laser technology, which do

not entail use of general anesthesia, and incur minimal superficial ablation alongside thermal cell activation and tissue rejuvenation, have raised the popularity of this treatment approach, particularly in clinical dermatologic and plastic surgery procedures [5]. The FemiLift CO₂ laser (Alma Laser, Israel) was focused through holographic lenses to deliver microablative CO₂ laser energy with an 81-pixel beam in a 9x9 mm template (**Figure 1**).

Application of such technology in the vulvo-vaginal area resulted in vaginal rejuvenation, manifested by thickening of vaginal epithelium, collagen deposition and neovascularization in the lamina propria [6]. The histological changes and relief of feminine discomfort, such as vaginal dryness and urinary incontinence, elicited by this technology [7], justify testing it as an alternative treatment for LS.

Case 1

A 71-year-old woman, treated in our clinic for 8 months, complained of intense vulvar and perianal itching, and presented extensive white lesions in the introitus, vulvar and clitoral areas (**Figures 2-3**); biopsy analysis confirmed LS. Topical therapy with Clobetasol 0.5% and 2% testosterone cream resulted in transient improvement. The patient remained symptomatic for six more months under this treatment, with no sexual activity.

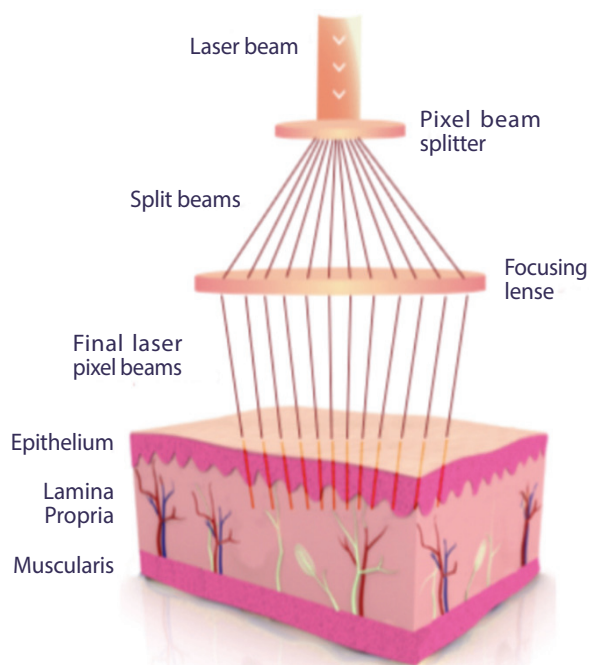
Histological assessments revealed hyperkeratosis, dermal hypotrophy, hydropic degeneration of basal epithelial cells, dermo-epidermal clefts, afibrillar papillary dermis with a frosted glass appearance, and inflammatory infiltrate rich in polymorphonuclear band and plasma cells.

Fractional/Pixel CO₂ laser therapy was initiated in June 2015. Three treatment sessions were conducted at one-month intervals. A topical anesthetic was applied before treatment. Three passes were made at each session, with the laser set at Low (10 Watts),

20 mJ/Pixel, 2 Hz in the first and second sessions, and Med (30 Watts), 10 mJ/Pixel, 2 Hz in the third session. Moisturizer with anesthetic cream was applied following treatment and for seven days thereafter.

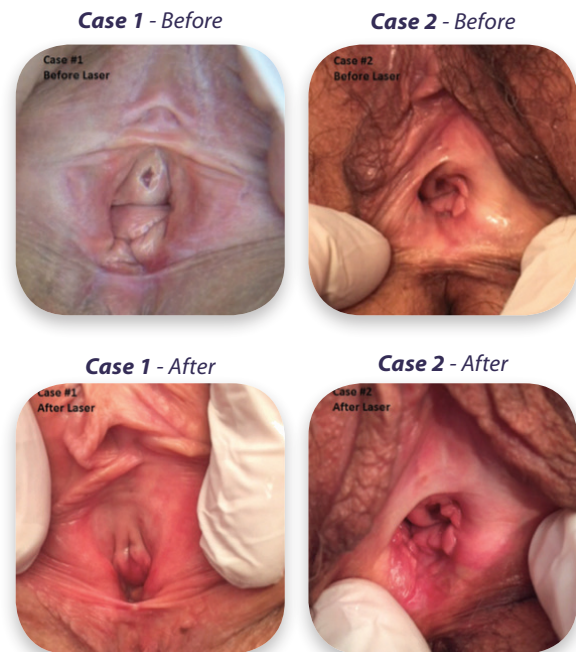
The patient became asymptomatic shortly after the third treatment session, and the vulva, introitus and clitoral areas looked healthy, with elastic closure of the introitus (**Figures 2-3**). Tissue appearance was maintained throughout the 6-month post-treatment follow-up period. Histological assessment of samples collected 45 days following the last treatment, showed a trophic epithelium with acanthotic areas, without superficial hyperkeratosis. A number of dermo-epidermal clefts were still apparent. The lamina propria appeared fibrillar and the hyaline band typical of LS, was absent. In addition, irregular spaces containing translucent material were observed, as was moderate inflammatory infiltrate.

FIGURE 1:



The CO₂ laser was focused through holographic lenses to deliver microablative CO₂ laser energy with an 81-pixel beam in a 9x9mm template.

FIGURE 2:



Physical appearance of the vulvar, clitoral and intolal areas before and after Fractional/Pixel CO₂ laser treatment. Left column - case 1, Right column - case 2.

Case 2

A 55-year-old woman, treated in our clinic for almost 3 years, complained of vaginal dryness, dyspareunia, intense itching and a narrow introitus. Extensive white lesions in the introitus, with bilateral symmetric “kissing lesions” were apparent (**Figure 2**).

Three years of therapy with Clobetasol 0.5%, Platelet Rich Plasma (PRP) and Testosterone cream 2% did not provide adequate relief; the patient reported transient improvements of itching, and intermittent symptoms. Biopsy confirmed Lichen Sclerosus. Pretreatment histological assessments revealed hyperkeratosis of the epidermis, with significant thinning and loss of the normal papillary pattern (**Figure 3**).

Vacuolar degeneration of the basal layer was also evident, yet typically mild, particularly in late stage lesions. Broad condensation of the dermal collagen, inflammatory lymphocytic infiltrate, scattered plasma cells, histiocytes and mast cells were dominant features (**Figure 3**).

In July 2015, the patient started a Fractional/Pixel CO₂ laser treatment course, comprised of three sessions, delivered at one-month intervals, under topical anesthesia (tetracaine-lidocaine), with three passes at each session. Laser settings at sessions one and two were low

power (10 Watts), 15 mJ/Pixel and at session three, were Medium power (30 Watts), 20 mJ/Pixel. Moisturizer with anesthetic cream was applied following treatments.

Shortly following the third treatment session (November 2015), the patient became asymptomatic, and a post-treatment clinical examination demonstrated improvement in the appearance of the introitus, and in elastic opening and closing (**Figure 2**). Post-treatment histology revealed a trophic epithelium with mild acanthosis, and areas with a visible increase in the number of cell layers.

In addition, the lamina propria contained loose collagen and no hyaline band was observed. The tissue samples featured irregular spaces containing translucent material (image gruyere cheese) in the papillary dermis, mild inflammatory infiltrate and poorly dilated vessels.

Masson's trichrome-stained samples exhibited a trophic epithelium, with a fibrillar appearance and light blue staining in the papillary area of the lamina propria, indicating the existence of type III collagen (**Figure 3**).

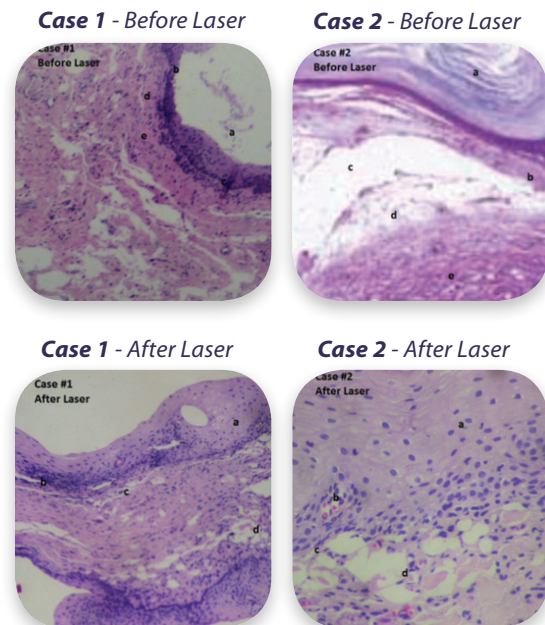
The patient reported improved sexuality, with occasional dyspareunia. The improved macroscopic appearance and clinical symptoms were maintained throughout the six-month follow-up period.

FIGURE 3:

Histological assessment of Masson's trichrome-stained tissue samples before versus after fractional CO₂ laser treatment. (Left column – case 1; right column – case 2).

Top row: Hyperkeratosis (a), dermal atrophy, hydroptic degeneration of the basal epithelial cells (b) dermo epidermal clefts (c) homogeneous papillary dermis, afibrillar with frosted glass appearance and edema (d), inflammatory infiltrate of polymorphonuclear band and plasma cells (e), inflammatory infiltrate of polymorphonuclear band and plasma cells (f).

Bottom row: Trophic epithelium without superficial hyperkeratosis (a), persistence in some basal cells hydroptic degeneration (b), persistence of some areas with dermo-epidermal clefts (c), lamina propria fibrillar with irregular spaces containing translucent material (d).



Histological assessment of Masson's trichrome-stained tissue samples Before (Upper) After (Lower) fractional CO₂ laser treatment

Discussion

Lichen sclerosus is diagnosed by typical characteristics, including histological signs of superficial sclerosis, hyperkeratosis, and significant epithelium thinning. Once confirmed, steroids are the first treatment choice, and improvement of symptoms is usually apparent within 2-3 weeks.

Topical corticosteroids, as anti-inflammatory agents, provide for symptomatic relief, but fail to restore histological architecture. Other steroid hormones, with or without immune-modulators, are used to address the lack of ovarian hormones in post-menopausal patients. Surgical intervention, including ablative CO₂ laser therapy, is typically considered to be a symptomatic treatment as well. However, the histological alterations observed in these two patients such as disintegrating fibrosis, stimulated collagen production in the lamina propria, and disappearance of the hyaline band, suggest a more comprehensive healing effect of the Fractional/Pixel CO₂ laser.

Recent publications describing Fractional/Pixel CO₂ laser therapy as an efficient means of reversing the typical post-menopausal vaginal wall histology to the premenopausal architecture [7], call for in-depth research to understand the underlying physiologic and pathophysiologic mechanisms. Most publications describing “vaginal rejuvenation” rely on subjective patient responses to questionnaires, such as the visual analogue scale (VAS), the International Consultation on Incontinence modular Questionnaire

(ICIQ-UI), or the Vaginal Health Index Score (VHI-S). Some of these articles describe histological remodeling and vaginal rejuvenation [6] and suggest the involvement of heat shock proteins 43, 47 and 70 in localized increases in specific cytokines, which consequently activate fibroblasts to produce new collagen and new blood vessels [8].

Didactic tools will be necessary to systematically monitor early and late consequences of Fractional/Pixel CO₂ laser treatment of LS and similar pathologies, and to test the hypothesis that thermal effects in the sup-epithelial layer trigger cellular activation.

Such studies will be essential in optimizing treatment protocols for a large variety of conditions involving feminine discomfort. Progress made in diagnostic and therapeutic technologies will inevitably stimulate in-depth research of external genital diseases and related symptoms.

If fractionated CO₂ laser therapy is confirmed an efficient modality, this treatment concept might represent a new strategy for providing more than just symptomatic relief, by also for eliciting a rejuvenation response, and serving as a platform to define other GSM treatment protocols. The improved quality of life in these two patients who did not respond to conventional medications, justifies prospective studies focusing on laser-modified vaginal histology.

References

1. Chi CC1, Kirtschig G, Baldo M, Brackenbury F, Lewis F, Wojnarowska F. Cochrane Database Syst Rev. Topical interventions for genital lichen sclerosis. 2011;7;(12).
2. Pugliese, JM; Morey, AF; Peterson, AC. Lichen Sclerosus: Review of the Literature and Current Recommendations for Management. J Urol, 2007; 178 (6): 2268–2276.
3. Abramov Y, Elchalal U, Abramov D, Goldfarb A, Schenker JG. Surgical treatment of vulvar lichen sclerosis: a review. Obstet Gynecol Surv. 1996;51(3):193-9.
4. Peterson CM, Lane JE, Ratz JL. Successful carbon dioxide laser therapy for refractory anogenital Lichen Sclerosus. Dermatol Surg. 2004;30(8):1148-51.
5. Berlin AL, Hussain M, Phelps R, Goldberg DJ. A prospective study of fractional scanned nonsequential carbon dioxide laser resurfacing: a clinical and histopathologic evaluation. Dermatol Surg. 2009;35:222-228.
6. Salvatore S, Leone Roberti Maggiore U, Athanasiou S, et al. Histological study on the effects of microablative Fractional/ Pixel CO₂ laser on atrophic vaginal tissue: an ex vivo study. Menopause. 2015;22(8):845-9.
7. Salvatore S, Napi RE, Zerbinati N, Calligaro A, Ferrero S, Orioni M, Candiani M, Maggiore ULR. A 12-week treatment with fractional CO₂ laser for vulvovaginal atrophy: a pilot study. Climacteric, 2014;17:363-369.
8. Dafforn TR, Della M, Miller AD. The molecular interaction of heat shock protein 47 (Hsp47) and their implications for collagen biosynthesis. J. Biochem 2001;276:49310-49319.