

Cryo-laser and cryo-sclerotherapy guided by augmented reality for telangiectasias, feeder, and small varicose vein treatment – The CLaCS technique white paper report

Roberto Kasuo Miyake¹, Eduardo Ramacciotti^{2,3*}

Roberto Kasuo Miyake¹, Eduardo Ramacciotti. Cryo-laser and cryo-sclerotherapy guided by augmented reality for telangiectasias, feeder, and small varicose vein treatment – The CLaCS technique white paper report. *J Phlebol Lymphol* 2019;12(1):1-7.

Keywords: Augmented reality; clacs; duplex ultrasound; telangiectasias; treatment; feeder veins; classifications; varicose veins

In this white paper, we describe the development of CLaCS, the acronym for Cryo-laser and cryo-sclerotherapy guided by augmented reality, a technique used for the treatment of telangiectasias, feeder, and small varicose veins.

INTRODUCTION

Varicose vein disease affects a large portion of the global population. It is estimated that half of the adult population have symptoms of venous disease (women 50-55% and men 40-50%) with half of these with visible varicose veins [1,2].

Standard treatments, despite reducing clinical symptoms, often do not deliver the expected aesthetical results. Effective treatment involves treating veins and spider veins, particularly those in the legs –unsightly vessels that can affect a patient’s self-esteem and their quality of life.

The treatment of spider veins in the lower limbs is often carried out by injection of different sclerosing agents, and despite its efficacy, it is not free of complications, from anaphylaxis to skin necrosis [3,4].

In 1995 it was introduced the treatment with intense pulsed light based on the concept of photo thermolysis. [5] A pulsed photothermal device (intense pulsed light source [IPLS]) has been developed to treat leg veins ranging in size from 0.1 to 3 mm in diameter. Vessel necrosis was induced from an intense pulsed light that penetrates through the skin and absorbed by the blood vessels based on the principle of selective photo-thermolysis.[5] Despite initial enthusiasm, the technique was later abandoned due to poor aesthetical results and skin burns. [6,7]

The use of Nd: Yag 1064 nm lasers followed the development of IPL systems. The Nd: Yag laser was also developed based on the concept of selective photothermolysis. By using a wavelength of light well absorbed by the target and pulse duration long enough to confine thermal injury spatially, a specific vascular injury could be produced. With better aesthetical results and with fewer complications than the IPL system, it is currently still the laser treatment of choice for small varicose veins.[8]

With the development of augmented reality (AR) to identify under the skin vessels, initially for venous punctures, our group decided to develop its technology also for varicose vein treatment.[9]

The association of all available techniques for the aesthetical treatment of varicose veins led to the development by our group of CLaCS, the acronym for Cryo-laser and cryo-sclerotherapy guided by AR for telangiectasias, feeder and small varicose veins treatment.

In this white paper, we describe the CLaCS treatment of telangiectasias and feeder vein(s)—not connected to refluxing perforator vein(s) and/or saphenous vein(s)—and how it can lead to excellent results with a low rate of recurrence and complications.

CLaCS technique

It is a medical technique to treat the combination of telangiectasias and the associated causative reticular veins (“feeder veins”) of the leg.

It employs the features: AR viewing of the feeder veins; application of transdermal laser energy to the feeder veins and overlying telangiectasias; injection of the feeder vein and surface telangiectasias with a Dextrose 75% -D75 (or other sclerosant agents at the physician discretion); and skin temperature protection and numbing of the skin with application of a flow of cold air throughout the procedure. A photograph is taken before and after the procedure in all patients. In CLaCS, the skin and the sclerosing agent are cooled by a cold air blower; skin cooling decreases pain both during laser and injection sclerotherapy. Low initial temperature also helps to protect the skin.

The purpose of CLaCS technique is to achieve efficacy through the synergy between the transdermal laser, injection sclerotherapy, and skin cooling. The transdermal laser has the ability to perform selective photo-thermolysis (penetrate the skin, without damage, and injure the vein).

The following is the detailed description of the CLaCS technique (Table 1)

TABLE 1: describes the sequence of CLaCS technique.

1. Previous photo documentation followed by

¹Miyake Clinic, Hiroshi Miyake Research Center, São Paulo, SP, Brazil

²Vascular Surgery, Santa Casa de São Paulo School of Medical Sciences, São Paulo, SP, Brazil.

³Hemostasis & Thrombosis Research Laboratories at Loyola University Medical Center, Maywood, IL, USA.

* **Correspondence:** Eduarado Ramacciotti, Vascular Surger, Santa Casa de São Paulo School of Medical Sciences, São Paulo, SP, Brazil, Tel: 09030-010; Email: eduardoramacciotti@gmail.com

Received date: October 23, 2019; **Accepted date:** October 30, 2019; **Published date:** November 06, 2019



This open-access article is distributed under the terms of the Creative Commons Attribution Non-Commercial License (CC BY-NC) (<http://creativecommons.org/licenses/by-nc/4.0/>), which permits reuse, distribution and reproduction of the article, provided that the original work is properly cited and the reuse is restricted to noncommercial purposes. For commercial reuse, contact reprints@pulsus.com

-
2. Ultrasound detection of feeder veins plus + AR evaluation
 3. Simultaneous cryo-laser treatment (Nd:Yag 1064 nm pulses with previous skin cooling using dermatological cooling devices) guided by AR with and followed by
 4. Cryo-sclerotherapy (injections of sclerosant agents) guided by AR (the vein-viewer device) using magnification loupes.
-

1. Photo documentation

Proper photo documentation is crucial for medical documentation as well as results follow-up for the entire treatment. A photograph should be made with an at least semi-professional machine—digital single-lens reflex (DSLR) —with an external flash. The flash head should be rotated 180 degrees and directed to the ceiling, which should be white. This way, using the automatic mode of the camera, we can obtain high-resolution photos without the need for photographic experience or expensive medical photo-documentation software/hardware. Tethering photography with Lightroom

(Adobe) can be used to provide before and after comparisons. Patients frequently forget how the lesion looked prior to treatment; showing the comparison helps them to evaluate the outcome.[10]

It is strongly recommended at least 20 pre-treatment photos; with the CLaCS technique, 40 pre-treatment photographs on average are taken, with and without AR. Only the pre and post photo documentation can provide objective evidence of the outcome. Neither the patient nor the doctor can appreciate the improvement without the use of photography. Figure 1 depicts an example of pre and post photos.

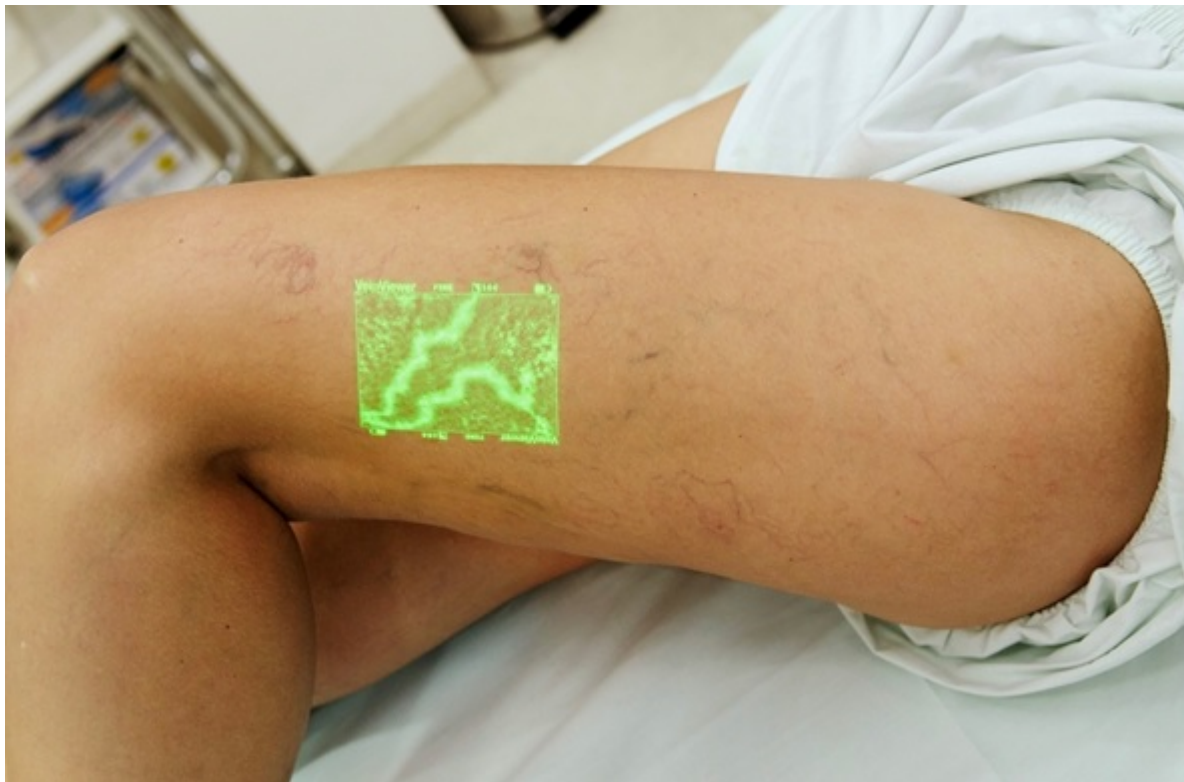

Figure 1A: Photograph before treatment.

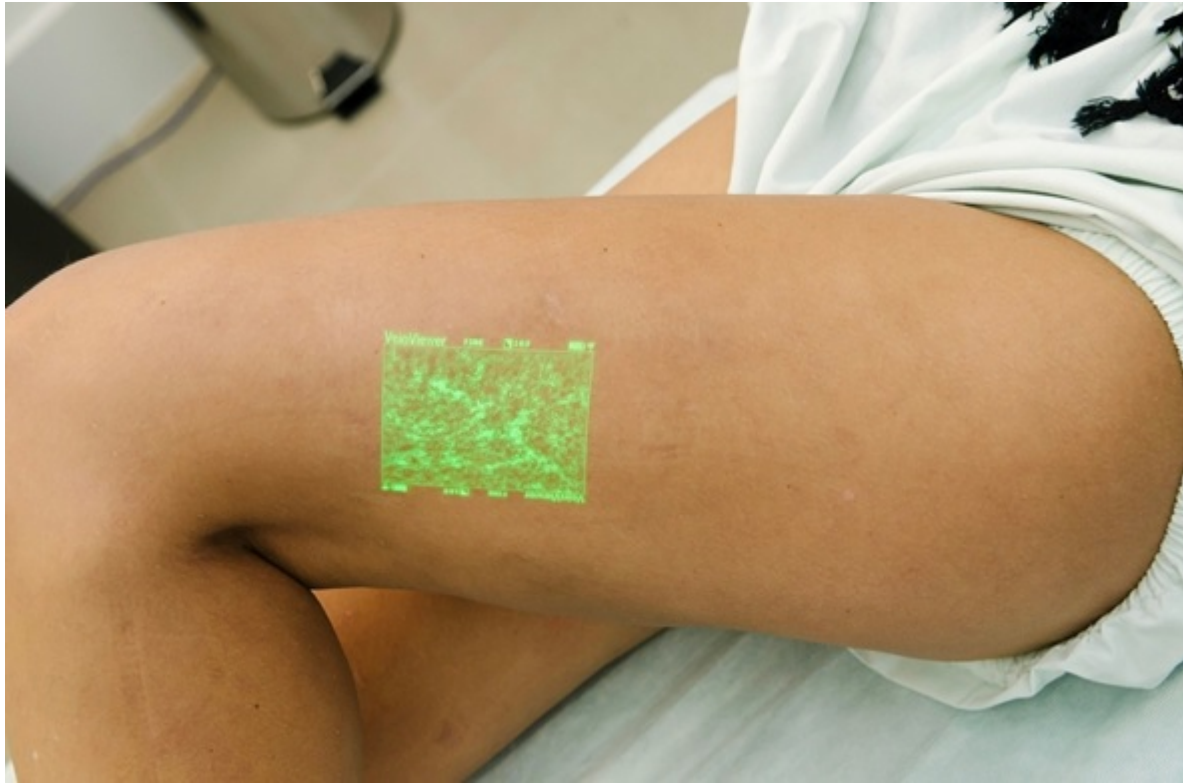

Figure 1(B): photograph after 3 CLaCS sessions

2. Ultrasound evaluation

Doppler ultrasound is performed in all patients, even in the asymptomatic ones (where reflux can be present in around 45% of patients)[11] with only aesthetical complaints. The objective of the ultrasound is to evaluate reflux from both the saphenous and perforator veins, its connections with feeder veins, and mapping superficial varicose veins, directing the CLaCS treatment. Ultrasound is also important to measure feeder veins diameters. Ultrasound evaluation helps to identify patients for proper CLaCS treatment. CLaCS can be performed from telangiectasias to feeder veins/small varicosities measuring up to 1.5mm in internal diameter. Larger vessels are treated with standard surgical phlebectomy.

3. Cryo-laser guided by AR treatment

The ideal laser for CLaCS is the neodymium-doped yttrium aluminum garnet (Nd: Yag 1064nm [nm]), long pulse (>15ms), large spot size (>6mm in diameter) laser. Such lasers typically have more than 1000W of power. Other lasers, such as 980nm wavelengths or small spot size lasers, generally have much less energy (10–30W). In CLaCS, the skin and the sclerosing agent are cooled by a cold air blower; skin cooling decreases pain both during laser and injection sclerotherapy. Low initial temperature also helps to protect the skin.

The use of augmented reality and duplex scan are substantial advances in phlebology. Regardless of the technique of choice for telangiectasias and

feeder veins, accurate diagnosis leads to better results and a lower complication rate. Augmented reality devices, such as the Vein Viewer (VV, Christie), can help with the diagnostic process.

The VV was designed in 2004 to help venous punctures in the upper limbs. It brightens skin with infrared light, films it with an infrared camera, processes the data, and projects the image onto the skin in a fraction of a second delay. It enables the vascular physician to map veins that are too shallow for ultrasound detection and too deep for naked eye visualization (e.g., 0.5–1.5mm in depth). By combining real images with images processed by computers, the VV is classified as augmented reality. If the infrared light can reach the veins and go back to the infrared camera, the transdermal laser, and the much more intense and collimated laser, also will. The AR improves the accuracy of both laser and sclerotherapy procedures. [9]

CLaCS was developed using the Nd: Yag 1064nm transdermal laser set to a 6mm spot size, (average 70J/cm² fluency, and 15ms pulse width). The heating generated by the transdermal laser damages the endothelial cells, leading to sub-endothelial blisters and media edema, with elastic fibers destruction. Figures 2A and 2B depict the histopathological analysis of subdermal veins treated with Nd: Yag 1064nm laser followed by standard phlebectomy (samples collected at our institution).

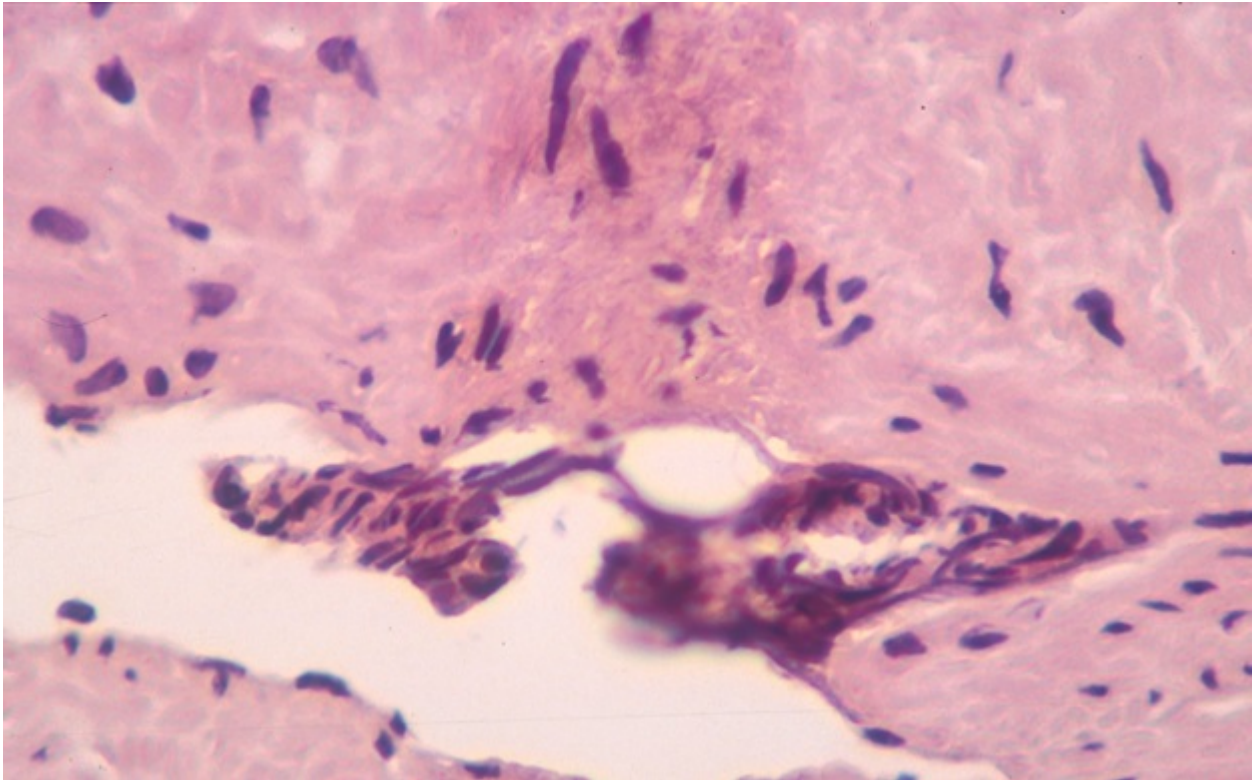


Figure 2A: Histopathological analysis of subdermal veins treated with ND: Yag 1064 nm laser followed by phlebectomy. The heating generated by the transdermal laser damages the endothelial cells, leading to sub-endothelial blisters with endothelial hypertrophy (varicose veins) with intra-endothelial vesicles.

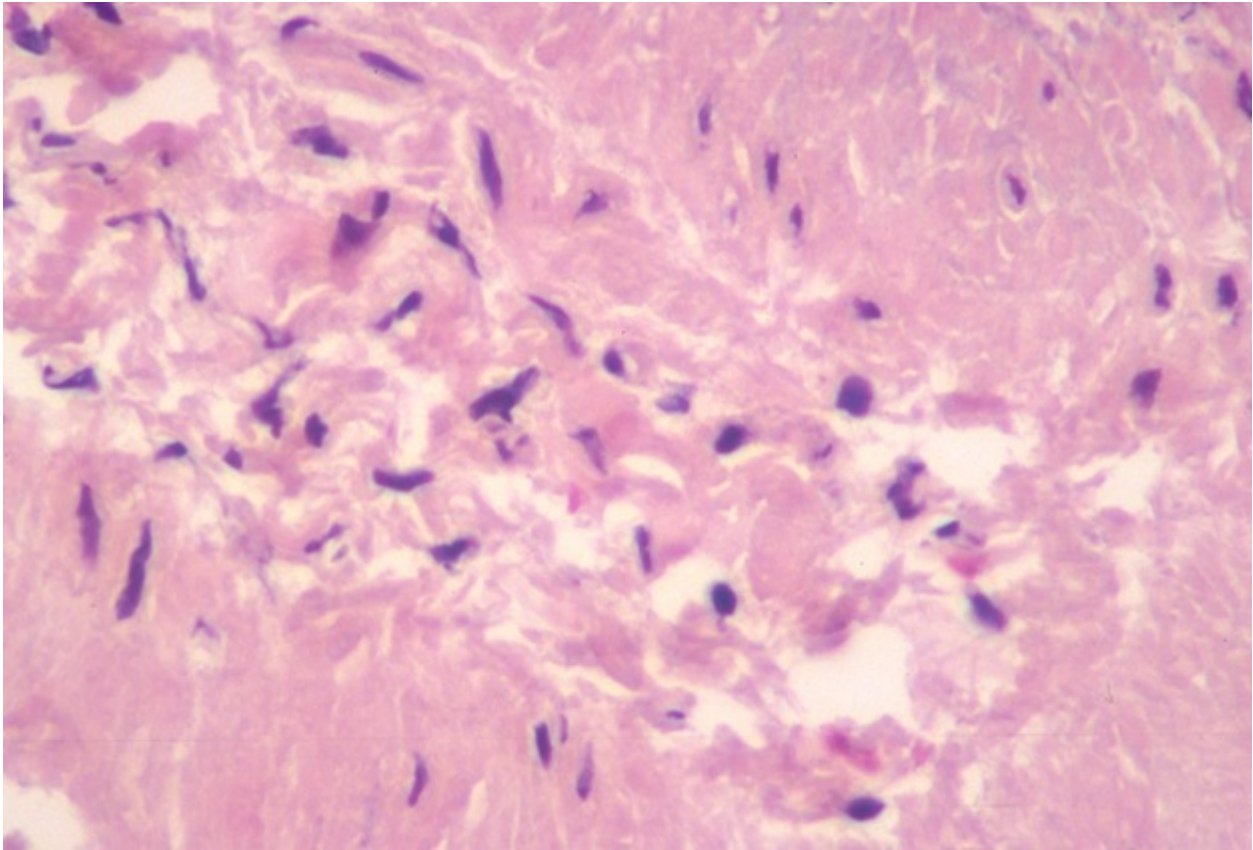


Figure 2B: Histopathological analysis of subdermal veins treated with ND: Yag 1064 nm laser followed by phlebectomy. The heating generated by the transdermal laser damages the endothelial cells, leading to media and inter-cellular edema, with elastic fibers destruction.

The transdermal laser is directed at the feeder veins identified through augmented reality, overlying and nearby the telangiectasia vessels that are being targeted with transdermal laser (Figure 3). After a few minutes, we see

a reduction of the internal diameter caused by tunica media swelling. If there is no immediate collapse, each segment 5mm vein or telangiectasia receives at least two laser shots. [8,12-14]

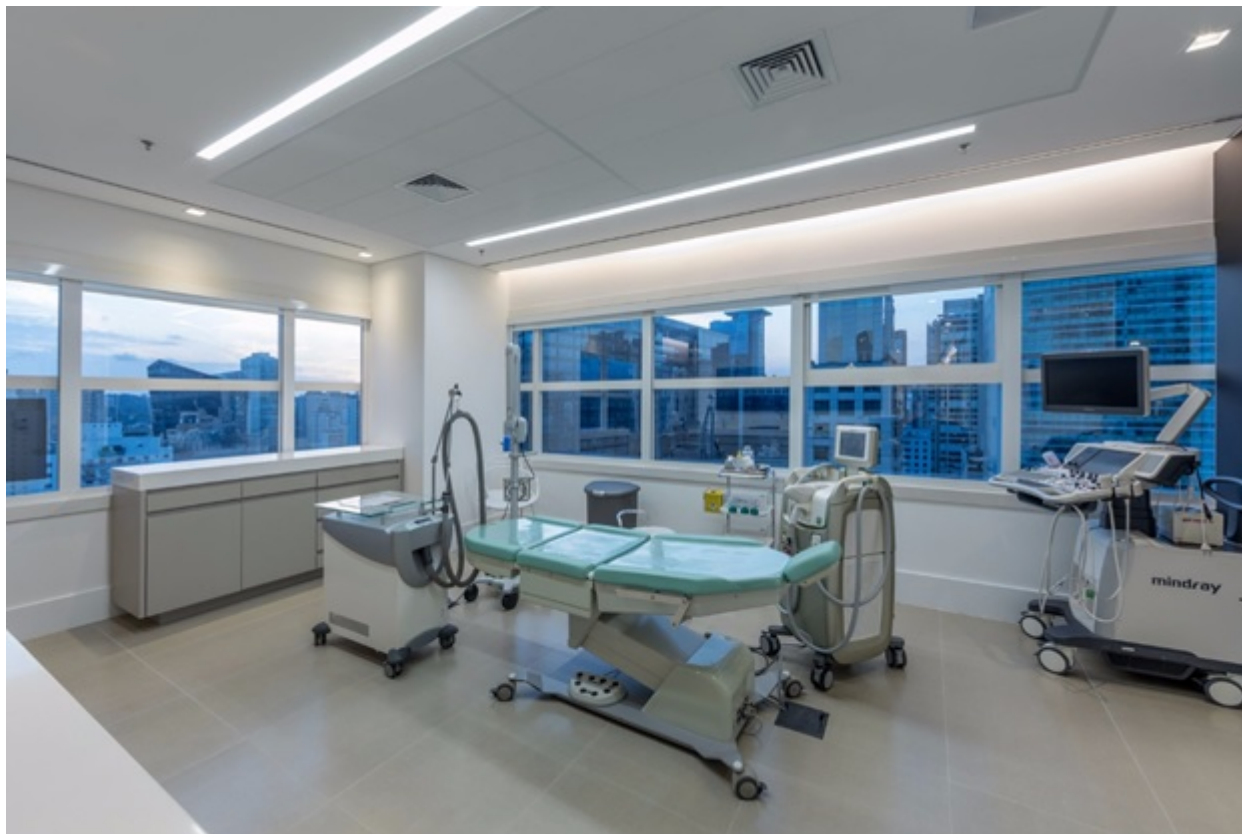

Figure 3: Phlebo-suite is a room prepared for diagnosis and aesthetic vein treatment. Ideally, it should include photo equipment, duplex ultrasound, augmented reality, skin cooler, transdermal laser, and magnification loupe. A complete phlebo-suite may also contain endovenous laser/radiofrequency devices.

4. Cryo-sclerotherapy guided by AR and augmentation loupes.

Sclerotherapy is made with D75, 3ml syringe, and 27G needle (due to high viscosity with D75, it is difficult to inject with 30G needles). The use of 2.5x magnifying loupe is advised as with magnification, the physician able to visualize the needle bevel filling with blood indicating the ideal injection point. After injection, a cotton ball is placed about 2-3mm and tape. All injections are made under the guidance of AR, the VeinViewer device.

Initial results with the CLaCS technique

Initial results with CLaCS were already reported elsewhere.[15] In summary, a total of 140 patients were evaluated. The mean age of patients was 37 years (16 to 72), with the prevalence of women (98%). Partial or total lesion improvement was obtained in 121 patients (86%), with satisfactory cosmetic results. An unsatisfactory outcome was observed in 19 patients (14%) due to no response or lesion worsening. These patients underwent phlebectomy. No allergic reactions, systemic reactions, skin burns, post-sclerotherapy matings, infections or crusting were observed. Temporary ecchymosis was observed in 30% of the cases, and intravenous coagula in 14% of them. No frostbite was registered due to cold air blowing. We concluded that, in this preliminary technique evaluation, CLaCS was effective and safe.[15]

Spreading CLaCS technique all over the world

Since the first publication of the AR technique for varicose vein treatment and subsequent CLaCS development, a significant number of vascular surgeons from all over the world contacted our group to learn this technique. CLaCS technique was presented on the last 3 Charing Cross meetings, and in all global Phlebology congresses (including the

International Union of Phlebology) since 2005. It is currently carried out in more than 20 countries, including the USA, Germany, France, Portugal, Latvia, Serbia, Russia, Brazil, Argentina, Colombia, Peru, Taiwan, Australia, by physicians that we proudly call "CLaCSers".

DISCUSSION

CLaCS is a synergistic combination of all techniques for the treatment of varicose veins. CLaCS combines the proper diagnostic tool (Doppler ultrasound + AR) with skin cooling followed by laser and sclerotherapy. It results in partial or total injury in the tunica media and endothelium caused by transdermal laser and injury caused by sclerosant agent. The edema caused by laser generates a trapping effect for the sclerosant agent. This trapping causes longer sclerosant agent contact time within the vein, increasing sclerotherapy effectiveness. The reduction of the internal diameter that may appear right after or minutes after transdermal laser, and it also helps to lower pigmentation rates.

The major concern with laser therapy is burning the skin. With the proper skin cooling device, followed by low energy pulses, it decreases these complications to minimal. This technique supports the concept of less laser energy with more exposure (2-3 laser passes per treated segments).

CLaCS technique follows the principle of "primum non nocere" or "first, do no harm". While the cost of CLaCS equipment is high, the price of a serious complication of an aesthetic procedure is much higher.[16] D75 in comparison to detergent agents leads to less anaphylaxis, and it is our agent of choice.[17]

We believe that these association of methods provides the best current approach for aesthetic phlebology treatments.

Major drawbacks: The technique is not fully validated in terms of efficacy. It is not an easy task to find objective means to evaluate proper efficacy

Cryo-laser and cryo-sclerotherapy guided by augmented reality for telangiectasias, feeder, and small varicose vein treatment – The CLaCS technique white paper report

endpoints for aesthetical phlebology. Pre and post photo evaluations, software analysis, and other methods are still undergoing evaluation. [10] Future studies addressing CLaCS effectiveness using objective methods are ongoing.

CONCLUSIONS

Detailed photo-documentation should be mandatory in superficial varicose vein treatment. Visualization and treatment of feeder veins are key to produce an optimal resolution on telangiectasia treatment and to prevent recurrences. CLaCS technique offers a synergistic approach to treat non-aesthetical varicose veins. CLaCS is a new and promising advanced technique, with future studies for its clinical validation warranted.

SUMMARY

Photo-documentation should be mandatory in aesthetic phlebology

Augmented reality helps diagnose feeder veins that may cause telangiectasia treatment failure.

CLaCS with D75 is a combination of light, sugar, and cold air.

CLaCS is a synergy of a "medium power" thermal sclerosing method with a "medium power" sclerosing injection gent (D75).

CLaCS can be carried out with different sclerosant agents

There are various brands of Nd: Yag 1064 nm laser devices

One of CLaCS highlights is effectiveness due to vein edema and contraction caused by the transdermal laser.

The synergy between methods causes less trapped blood and thus a shallow hyperpigmentation rate.

New validating studies are warranted.

REFERENCES

1. Bergan JJ, Schmid-Schonbein GW, Smith PD, et al. Chronic venous disease. *N Engl J Med* 2006; 355:488-498.
2. Callam MJ. Epidemiology of varicose veins. *Br J Surg* 1994;81(2):167-173.
3. Rabe E, Pannier F. Sclerotherapy of varicose veins with polidocanol based on the guidelines of the German Society of Phlebology. *Dermatol Surg* 2010; 36 Suppl 2:968-275.
4. Miyake RK, King JT, Kikuchi R, et al. Role of injection pressure, flow and sclerosant viscosity in causing cutaneous ulceration during sclerotherapy. *Phlebology* 2012;27(8):383-389.
5. Anderson RR, Parrish JA. Selective photothermolysis: precise microsurgery by selective absorption of pulsed radiation. *Science* 1983;220 (4596):524-527.
6. Goldman MP, Eckhouse S. Photothermal sclerosis of leg veins. ESC Medical Systems, LTD Photoderm VL Cooperative Study Group. *Dermatol Surg* 1996;22(4):323-330.
7. Miyake RK, Zeman HD, Duarte FH, et al. Imaging: a new method of near infrared imaging, where a processed image is projected onto the skin for the enhancement of vein treatment. *Dermatol Surg* 2006;32(8):1031-1038.
8. Sadick NS. Laser treatment of leg veins. *Skin Therapy Letter* 2004;9(9):6-9.
9. Miyake RK, Miyake H, Kauffman P. Skin temperature measurements during intense pulsed light emission. *Dermatol Surg* 2001;27(6):549-554.
10. Santiago FR, Piscoya M, Chi YW. Change in perception of sclerotherapy results after exposure to pre-post intervention photographs. *Phlebology* 2018;33(4):282-287.
11. Engelhorn CA, Engelhorn AL, Cassou MF, et al. Patterns of saphenous venous reflux in women presenting with lower extremity telangiectasias. *Dermatol Surg* 2007;33(3):282-288.
12. Baumler W, Ulrich H, Hartl A, et al. Optimal parameters for the treatment of leg veins using Nd:YAG lasers at 1064 nm. *Br J Dermatol* 2006;155(2):364-371.
13. Kono T, Yamaki T, Ercocen AR, et al. Treatment of leg veins with the long pulse dye laser using variable pulse durations and energy fluences. *Lasers in Surgery and Medicine* 2004;35(1):62-67.
14. Trelles MA, Allones I, Martin-Vazquez MJ, et al. Long pulse Nd:YAG laser for treatment of leg veins in 40 patients with assessments at 6 and 12 months. *Lasers Surg Med* 2004;35(1):68-76.
15. Miyake RK. Cryo-laser and cryo-sclerotherapy guided by Augmented Reality Report of 140 Cases. *Phlebologie -Stuttgart* 2014; 43(5):257-261.
16. Forlee MV, Grouden M, Moore DJ, et al. Stroke after varicose vein foam injection sclerotherapy. *J Vasc Surg* 2006;43(1):162-164.
17. Parsi K. Paradoxical embolism, stroke and sclerotherapy. *Phlebology* 2012;27(4):147-167.